A long-term follow-up study of Adenoviral (AdCD40L) Immunotherapy of Canine Malignant Melanoma

Henrikson J[1], S Saellström[2*], A Sadeghi[3], A Loskog[3], T Segall[4], O Korsgren[3], T H Tötterman[3], H Rönnberg[1]

[1]Center of Clinical Comparative Oncology (C_3O), Department of Clinical Sciences, Faculty of Veterinary Medicine and Animal Science, Swedish University of Agricultural Sciences (SLU), Uppsala, Sweden
[2]University Animal Hospital, Swedish University of Agricultural Sciences (SLU), Uppsala, Sweden,
[3]Department of Immunology, Genetics and Pathology, Uppsala University, Uppsala, Sweden, [4]National Veterinary Institute, Department of Pathology and Wildlife Diseases, Uppsala, Sweden.

Materials and Methods:

- A study of local Adenovector huCD40L immunogene (AdCD40L) treatment in 32 cases of malignant Canine Melanomas (CM).
- 22 oral, 5 skin 3 ungual, 1 nasal and 1 conjunctival.
- WHO-stage I;8, II;8, III;13 and IV;3 dogs.
- AdCD40L intratumoral injections (1-7, with a 7 days cycle) were followed by cytoreductive surgery in 20 cases, where 12 cases had immunotherapy only.

Results:

- After treatment, tumor tissue was infiltrated with lymphocytes suggesting immune activation both at the injection site and at metastases peripheral from the injection site.
- Best overall response was: 5 CR, 7 PR, 3 SD and 2 PD according to WHO-response criteria.
- At abstract submission median survival was 168 days (20-3000) and 1 of the dogs were still alive.
- Two of the deceased dogs were euthanized for causes other than CM.
- Transient fever and swelling at the injection site in some dogs were the only observed adverse event.

Left: Dog with oral melanoma in the maxilla before treatment.
Right: Same dog one week after intratumoral AdCD40L injection.

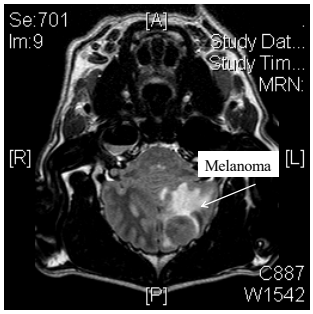

MR picture of a dog with malignant melanoma metastasis in the brain.

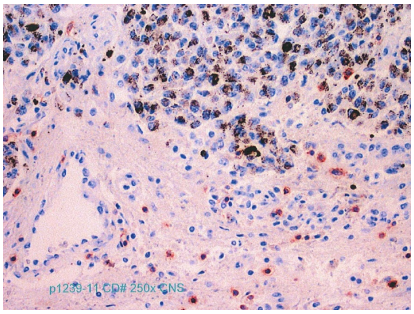

Immuno histochemistry showed a marked increase in infiltrating T-lymphocytes in post treatment samples from a metastasis in the brain of a dog. This suggest an abscopal effect with immune activation also at metastases peripheral from the injection site.

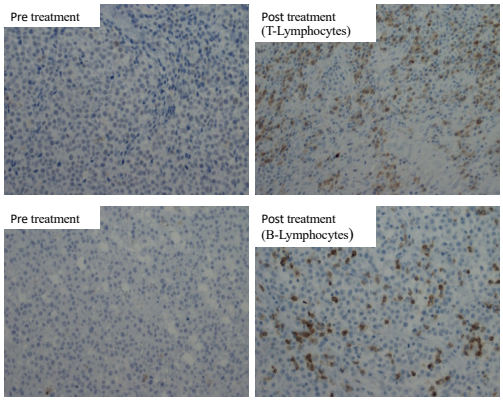

Immunohistochemistry also showed a marked increase in infiltrating T-lymphocytes and B-lymphocytes in post treatment samples (right) compared to pretreatment samples (left). This suggest immune activation at the injection site post treatment.

Canine melanomas (CM):

- Aggressive with a high metastatic potential.
- Surgery, radiotherapy and chemotherapy are seldom curative in advanced stages.
- It is proposed that human melanomas and CM share the same genetic factors leading to tumor development and metastatic spread.
- CM is a more accurate model for human melanoma than traditional murine models since dogs are outbred, immune competent and share the same environment as humans. Their tumors have a spontaneous origin.
- The homology of the human and the canine CD40L molecule is 85%.

Dogs makes excellent models for human malignant melanomas

Conclusions:

- The AdCD40L vaccine is easy to administer intra- and peritumorally.
- Only minor side effects.
- Shows **anti-tumor responses**, both at the **injection site** and **in peripheral metastases**.
- Local AdCD40L immunogene therapy is beneficial and safe in malignant melanoma in dogs.

** References can be provided upon request by Dr Saellström*